

The Skeletal System

How strange we would look without our skeleton! It is the skeleton that provides us with the rigid, supportive framework that gives shape to our bodies. But this is just the beginning, because the skeleton also protects the organs beneath it, maintains homeostasis of blood calcium, produces blood cells, and assists the muscular system in providing movement for us.

After reviewing the microscopic structure of bone and cartilage, you will understand how skeletal tissues are formed, their differences, and their importance in the human body. Your microscopic investigation will make the study of this system easier as you logically progress from this view to macroscopic bone formation and growth and visualize the structure of long bones.

The skeleton is divided into two main divisions: the axial skeleton and the appendicular skeleton. All of the 206 bones of the human body may be classified into one of these two areas. Although men and women have the same number and types of bones, subtle differences exist between a man's and a woman's skeleton. These structural differences provide us with insight into the functional differences between men and women.

Three types of joints exist in the body. They are classified according to the degree of movement they allow in the body. They are synarthroses, amphiarthroses, and diarthroses. It is important to have a knowledge of these joints to understand how movement is facilitated by articulations.

TOPICS FOR REVIEW

Before progressing to Chapter 8, you should familiarize yourself with the functions of the skeletal system, the structure and function of bone and cartilage, bone formation and growth, and the types of joints found in the body. Additionally, your understanding of the skeletal system should include identification of the two major subdivisions of the skeleton, the bones found in each area, and any differences that exist between a man's and a woman's skeleton. Your study should conclude with a review of the major skeletal disorders.

FUNCTIONS OF THE SKELETAL SYSTEM

TYPES OF BONES

STRUCTURE OF LONG BONES

Fill in the blanks.

1. There are _____ types of bones.
2. The _____ is the hollow area inside the diaphysis of a bone.
3. A thin layer of cartilage covering each epiphysis is the _____.
4. The _____ lines the medullary cavity of long bones.
5. _____ is used to describe the process of blood cell formation.
6. Blood cell formation is a vital process carried on in _____.
7. The _____ is a strong fibrous membrane that covers a long bone everywhere except at joint surfaces.
8. Bones may be classified by shape. Those shapes include _____, _____, and _____.
9. Bones serve as a safety-deposit box for _____, a vital substance required for normal nerve and muscle function.
10. As muscles contract and shorten, they pull on bones and thereby _____ them.

► *If you had difficulty with this section, review pages 163-165.*

MICROSCOPIC STRUCTURE OF BONE AND CARTILAGE

Match each term on the left with its corresponding description on the right.

Group A

- | | |
|----------------------|---------------------------------------|
| _____ 11. Trabeculae | A. Outer covering of bone |
| _____ 12. Compact | B. Dense bone tissue |
| _____ 13. Spongy | C. Fibers embedded in a firm gel |
| _____ 14. Periosteum | D. Needle-like threads of spongy bone |
| _____ 15. Cartilage | E. Ends of long bones |

Group B

- | | |
|----------------------------|------------------------------------|
| _____ 16. Osteocytes | A. Connect lacunae |
| _____ 17. Canaliculi | B. Cartilage cells |
| _____ 18. Lamellae | C. Structural unit of compact bone |
| _____ 19. Chondrocytes | D. Bone cells |
| _____ 20. Haversian system | E. Ring of bone |

► *If you had difficulty with this section, review pages 165-168.*

BONE FORMATION AND GROWTH

If the statement is true, write "T" in the answer blank. If the statement is false, correct the statement by circling the incorrect term and writing the correct term in the answer blank.

- _____ 21. When the skeleton forms in a baby before birth, it consists of cartilage and fibrous structures.
- _____ 22. The diaphyses are the ends of the bone.
- _____ 23. Bone-forming cells are known as *osteoclasts*.
- _____ 24. It is the combined action of osteoblasts and osteoclasts that sculpts bones into their adult shapes.
- _____ 25. The point of articulation between the epiphysis and diaphysis of a growing long bone is susceptible to injury if over-stressed.
- _____ 26. The epiphyseal plate can be seen in both external and cutaway views of an adult long bone.
- _____ 27. The shaft of a long bone is known as the *articulation*.
- _____ 28. Cartilage in the newborn becomes bone when it is replaced with calcified bone matrix deposited by osteoblasts.
- _____ 29. When epiphyseal cartilage becomes bone, growth begins.
- _____ 30. The epiphyseal cartilage is visible, if present, on x-ray films.

► If you had difficulty with this section, review pages 168-170.

DIVISIONS OF SKELETON

Circle the correct answer.

31. Which of the following is/are *not* a part of the axial skeleton?
- Scapula
 - Cranial bones
 - Vertebra
 - Ribs
 - Sternum
32. Which one of the following is *not* a cranial bone?
- Frontal
 - Parietal
 - Occipital
 - Lacrimal
 - Sphenoid
33. Which of the following is *not* correct?
- A baby is born with a straight spine.
 - In the adult, the sacral and thoracic curves are convex.
 - The normal curves of the adult spine provide greater strength than a straight spine.
 - A curved structure has more strength than a straight one of the same size and materials.
34. True ribs:
- Attach to the cartilage of other ribs
 - Do not attach to the sternum
 - Attach directly to the sternum without cartilage
 - Attach directly to the sternum by means of cartilage

35. The bone that runs along the lateral side of your forearm is the:
 A. Humerus
 B. Ulna
 C. Radius
 D. Tibia
36. The shinbone is also known as the:
 A. Fibula
 B. Femur
 C. Tibia
 D. Ulna
37. The bones in the palm of the hand are called:
 A. Metatarsals
 B. Tarsals
 C. Carpals
 D. Metacarpals
38. Which one of the following is *not* a bone of the upper extremity?
 A. Radius
 B. Clavicle
 C. Humerus
 D. Ilium
39. The heel bone is known as the:
 A. Calcaneus
 B. Talus
 C. Metatarsal
 D. Phalanges
40. The mastoid process is part of which bone?
 A. Parietal
 B. Temporal
 C. Occipital
 D. Frontal
41. When a baby learns to walk, which area of the spine becomes concave?
 A. Lumbar
 B. Thoracic
 C. Cervical
 D. Coccyx
42. Which bone is the "funny" bone?
 A. Radius
 B. Ulna
 C. Humerus
 D. Carpal
43. There are how many pair of true ribs?
 A. 14
 B. 7
 C. 5
 D. 3
44. The 27 bones in the wrist and the hand allow for more:
 A. Strength
 B. Dexterity
 C. Protection
 D. Red blood cell products
45. The longest bone in the body is the:
 A. Tibia
 B. Fibula
 C. Femur
 D. Humerus
46. Distally, the _____ articulates with the patella.
 A. Femur
 B. Fibula
 C. Tibia
 D. Humerus
47. Which bones form the cheek bones?
 A. Mandible
 B. Palatine
 C. Maxillary
 D. Zygomatic
48. In a child, there are five of these bones. In an adult, they are fused into one.
 A. Pelvic
 B. Lumbar vertebrae
 C. Sacrum
 D. Carpals
49. The spinal cord enters the cranium through a large hole (foramen magnum) in which bone?
 A. Temporal
 B. Parietal
 C. Occipital
 D. Sphenoid

JOINTS (ARTICULATIONS)

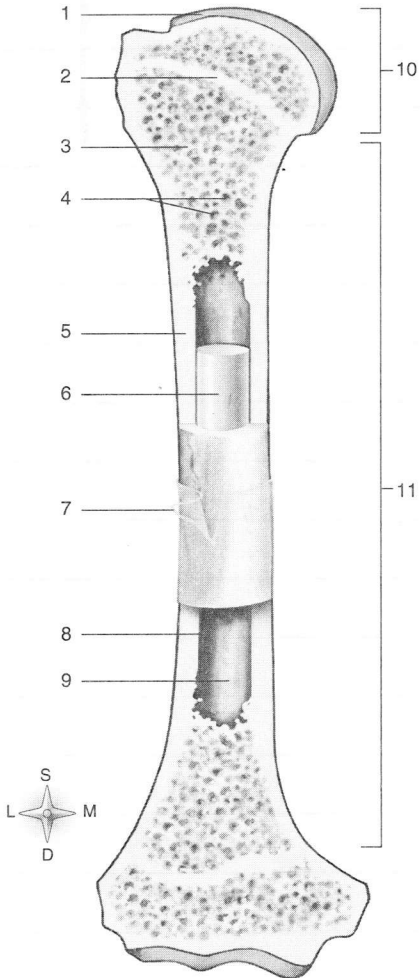
Circle the correct answer.

77. Freely movable joints are (*amphiarthroses* or *diarthroses*).
78. The sutures in the skull are (*synarthrotic* or *amphiarthrotic*) joints.
79. All (*diarthrotic* or *amphiarthrotic*) joints have a joint capsule, a joint cavity, and a layer of cartilage over the ends of the two joining bones.
80. (*Ligaments* or *Tendons*) grow out of periosteum and attach two bones together.
81. The (*articular cartilage* or *epiphyseal cartilage*) absorbs jolts.
82. Gliding joints are the (*least movable* or *most movable*) of the diarthrotic joints.
83. The knee is the (*largest* or *smallest*) joint.
84. Hinge joints allow motion in (2 or 4) directions.
85. The saddle joint at the base of each of our thumbs allows for greater (*strength* or *mobility*).
86. When you rotate your head, you are using a (*gliding* or *pivot*) joint.

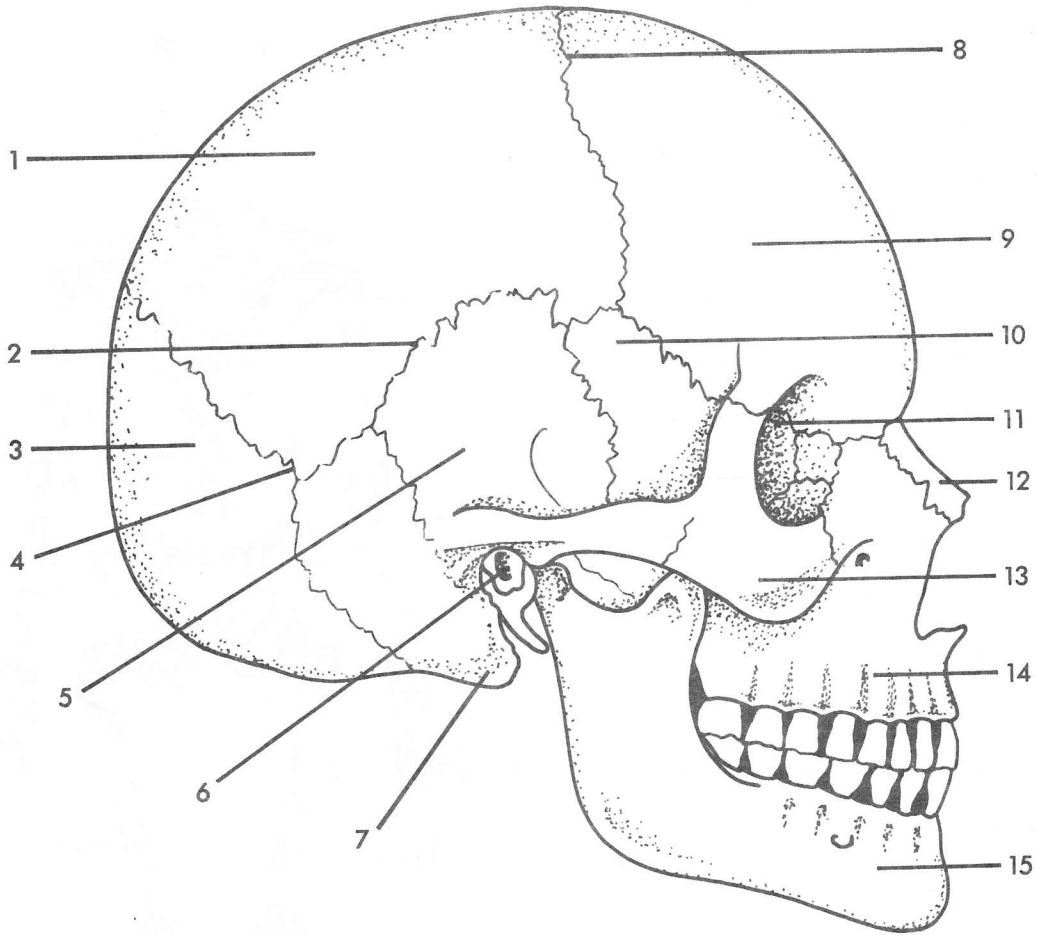
▶ *If you had difficulty with this section, review pages 185-191.*

LONGITUDINAL SECTION OF LONG BONE

- 1. _____
- 2. _____
- 3. _____
- 4. _____
- 5. _____
- 6. _____
- 7. _____
- 8. _____
- 9. _____
- 10. _____
- 11. _____

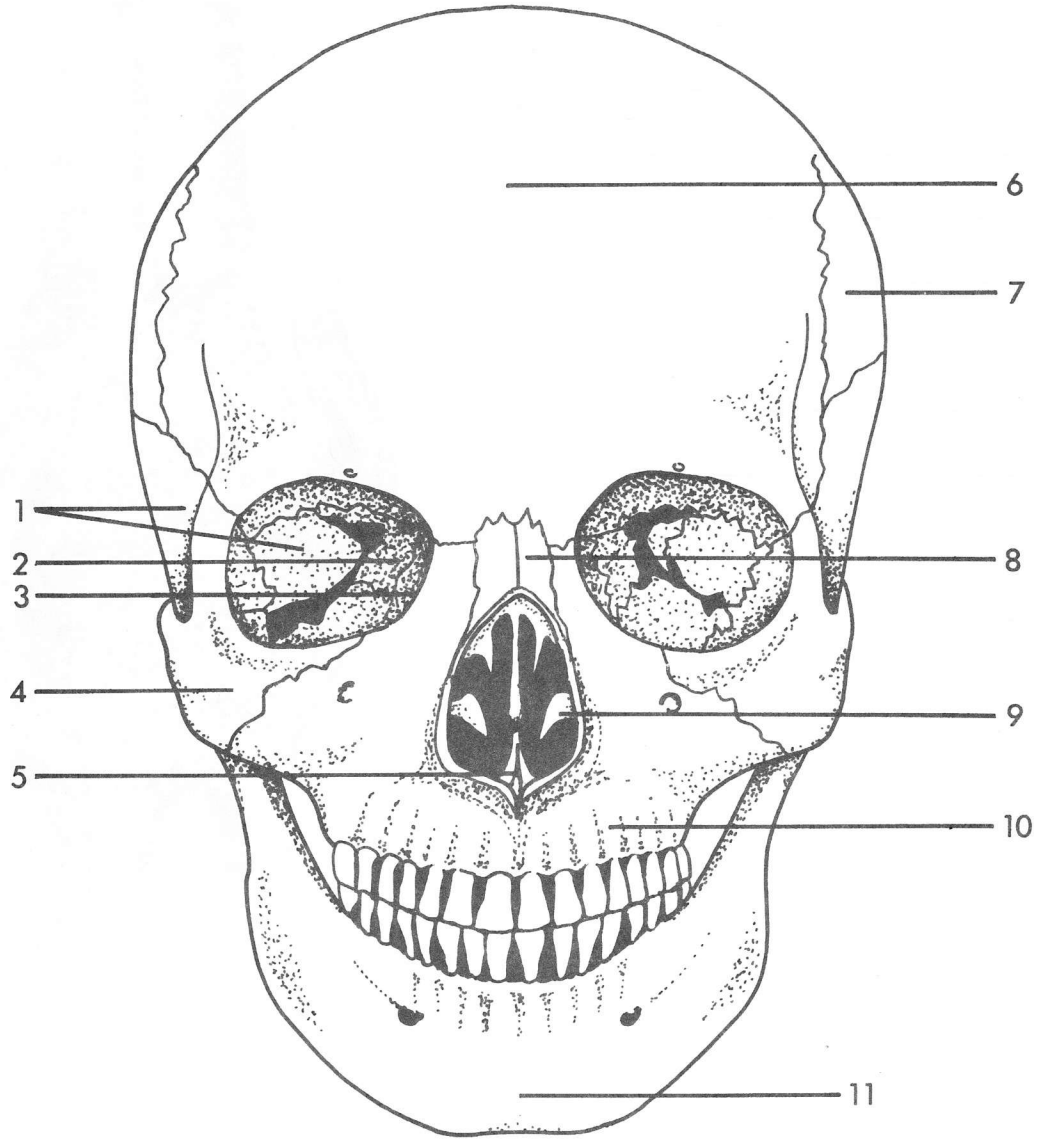


SKULL VIEWED FROM THE RIGHT SIDE



- | | |
|----------|-----------|
| 1. _____ | 9. _____ |
| 2. _____ | 10. _____ |
| 3. _____ | 11. _____ |
| 4. _____ | 12. _____ |
| 5. _____ | 13. _____ |
| 6. _____ | 14. _____ |
| 7. _____ | 15. _____ |
| 8. _____ | |

SKULL VIEWED FROM THE FRONT



- | | |
|----------|-----------|
| 1. _____ | 7. _____ |
| 2. _____ | 8. _____ |
| 3. _____ | 9. _____ |
| 4. _____ | 10. _____ |
| 5. _____ | 11. _____ |
| 6. _____ | |

STRUCTURE OF A DIARTHROTIC JOINT

1. _____
2. _____
3. _____
4. _____
5. _____
6. _____
7. _____
8. _____
9. _____

