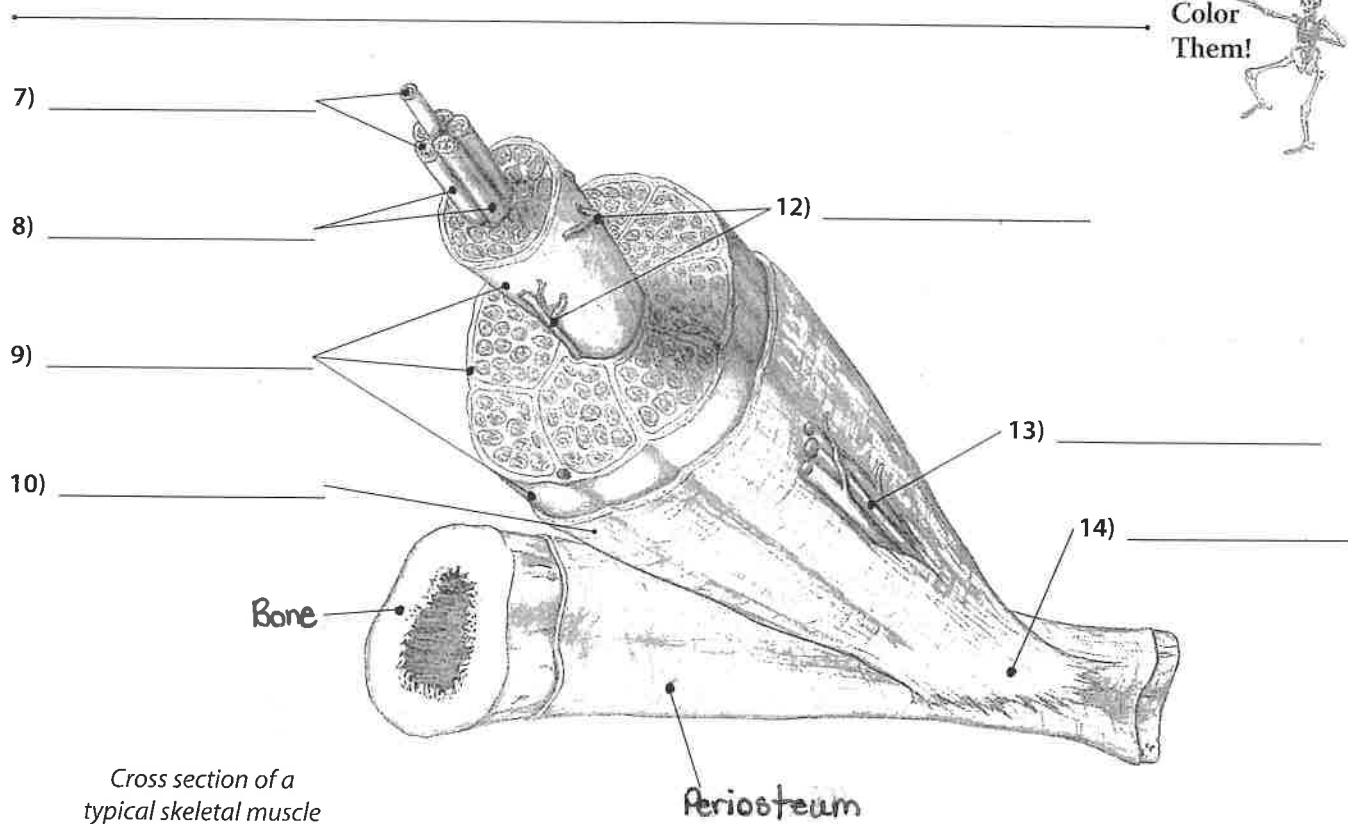
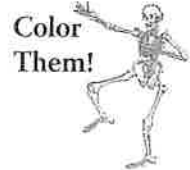
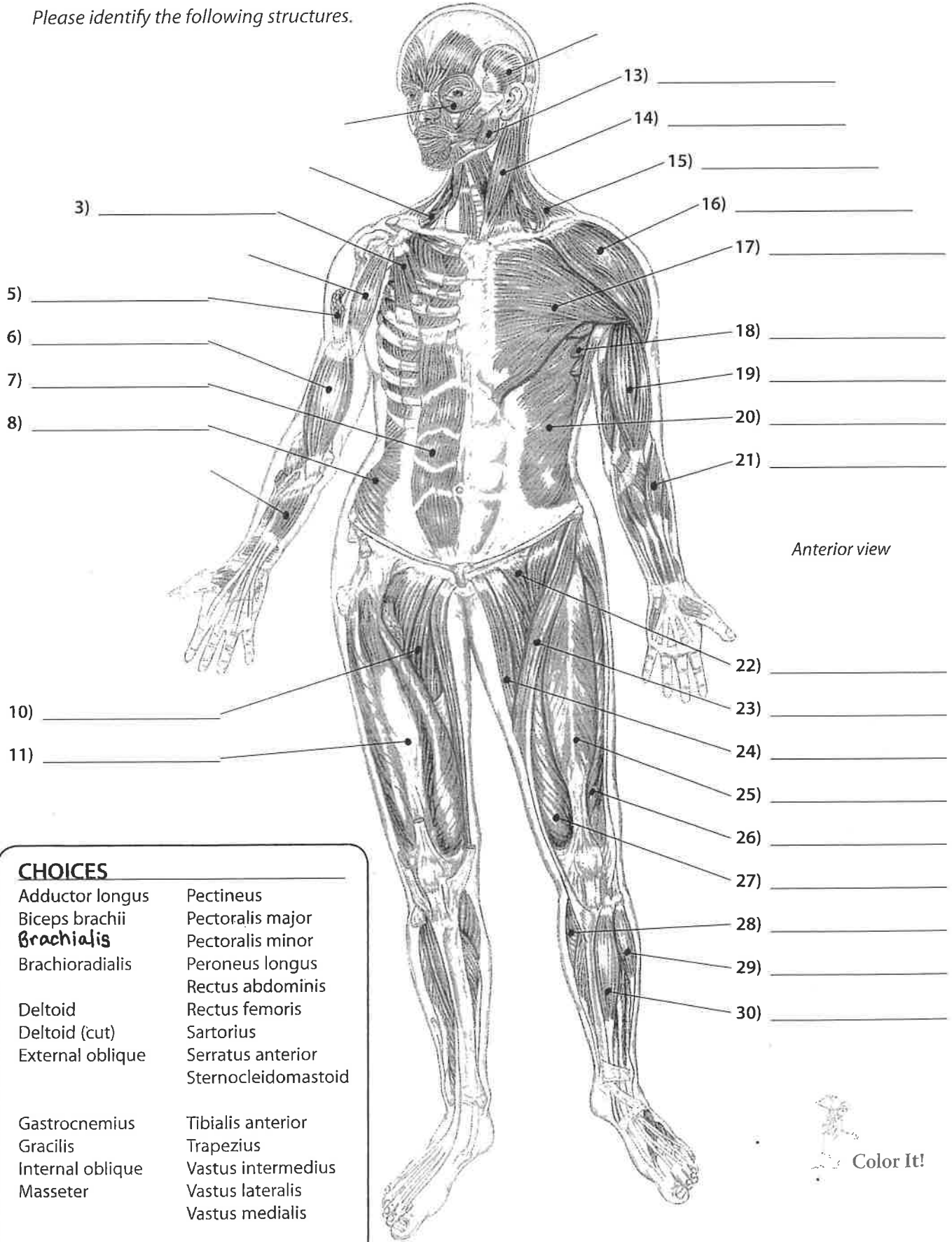
Cross section of a typical skeletal muscle

CHOICES

Blood vessels	Epimysium	Perimysium
Endomysium	Muscle fibers	Tendon
	Neurovascular bundle	



Please identify the following structures.



Anterior view

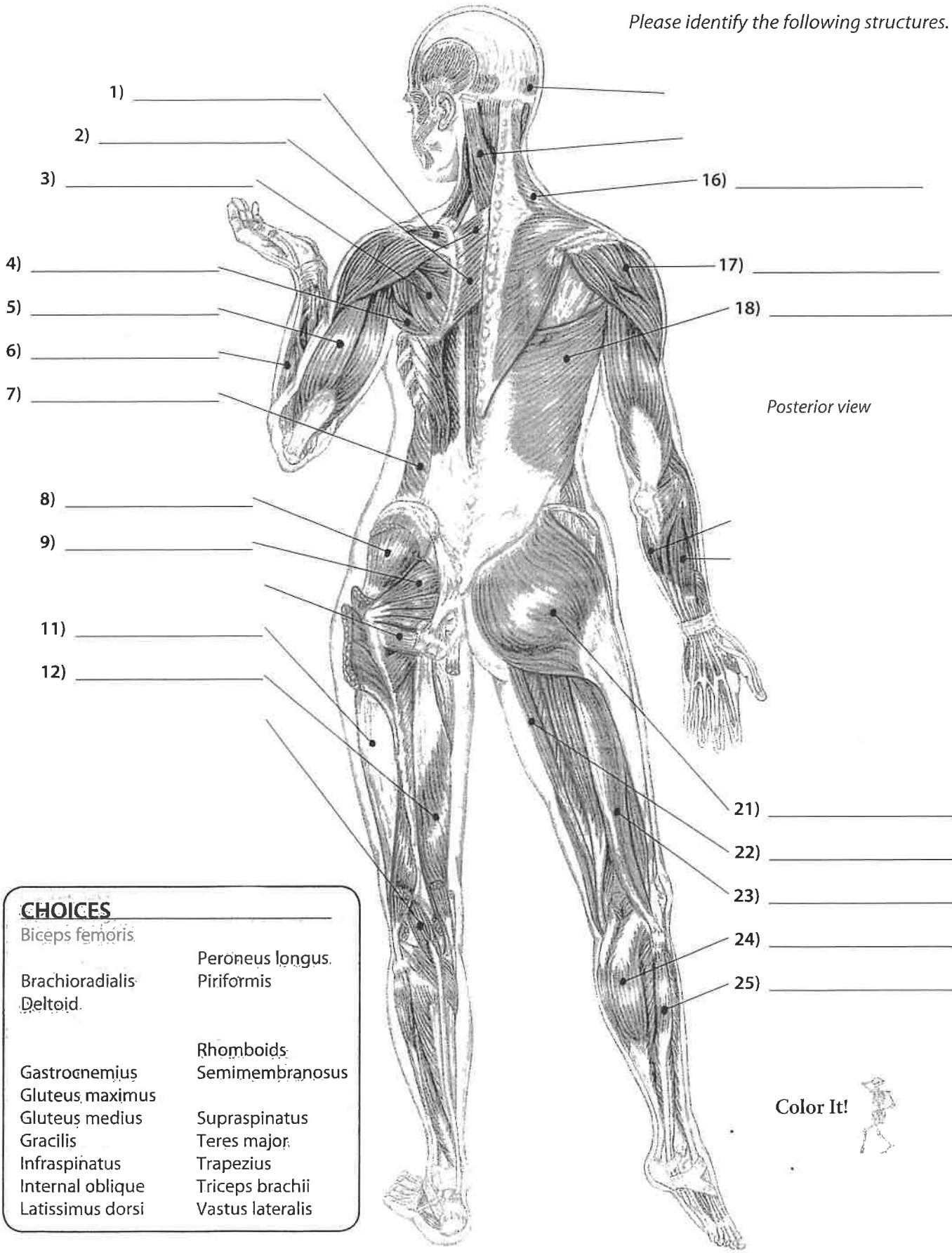
CHOICES

Adductor longus	Pectineus
Biceps brachii	Pectoralis major
Brachialis	Pectoralis minor
Brachioradialis	Peroneus longus
	Rectus abdominis
Deltoid	Rectus femoris
Deltoid (cut)	Sartorius
External oblique	Serratus anterior
	Sternocleidomastoid
Gastrocnemius	Tibialis anterior
Gracilis	Trapezius
Internal oblique	Vastus intermedius
Masseter	Vastus lateralis
	Vastus medialis





Please identify the following structures.



- CHOICES**
- | | |
|------------------|------------------|
| Biceps femoris | Peroneus longus. |
| Brachioradialis | Piriformis |
| Deltoid. | |
| | Rhomboids |
| Gastrocnemius | Semimembranosus |
| Gluteus maximus | |
| Gluteus medius | Supraspinatus |
| Gracilis | Teres major. |
| Infraspinatus | Trapezius |
| Internal oblique | Triceps brachii |
| Latissimus dorsi | Vastus lateralis |

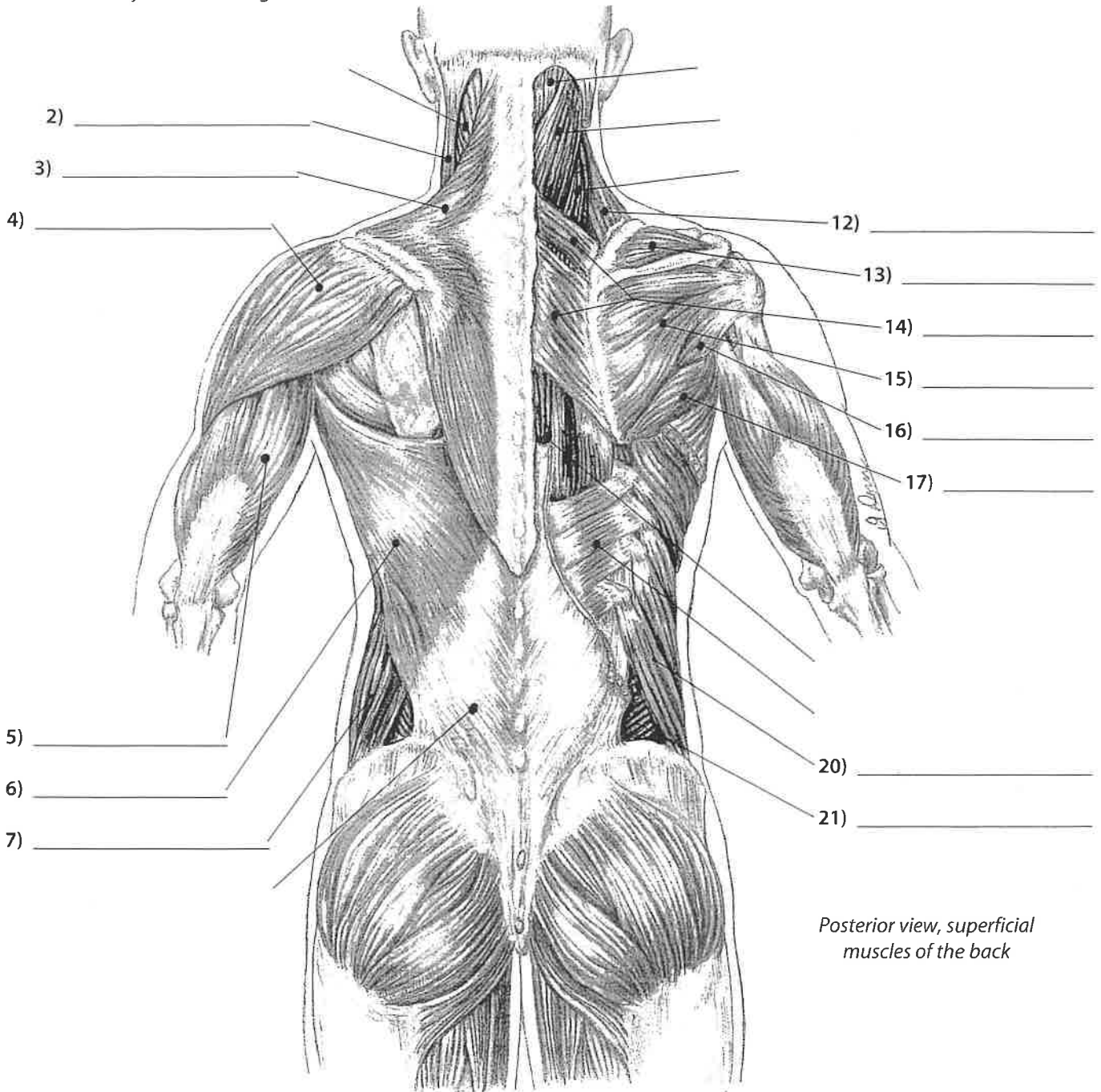
Color It!



Spine and Thorax

Muscles of the Spine and Thorax #1

Please identify the following structures.



Posterior view, superficial muscles of the back

Spine & Thorax

CHOICES

Deltoid	Rhomboids	Supraspinatus
External oblique (2)		Teres major
Infraspinatus		Teres minor
Internal oblique		
Latissimus dorsi	Sternocleidomastoid	Trapezius
Levator scapula		Triceps brachii



Pelvis and Thigh

Muscles of the Pelvis and Thigh #1

Please identify the following structures.

1) + 3) = _____

1) _____

2) _____

3) _____

5) _____

6) _____

7) _____

8) _____

9) _____

10) _____

11) _____

12) _____

13) _____

Anterior view of right hip and thigh

Pelvis & Thigh

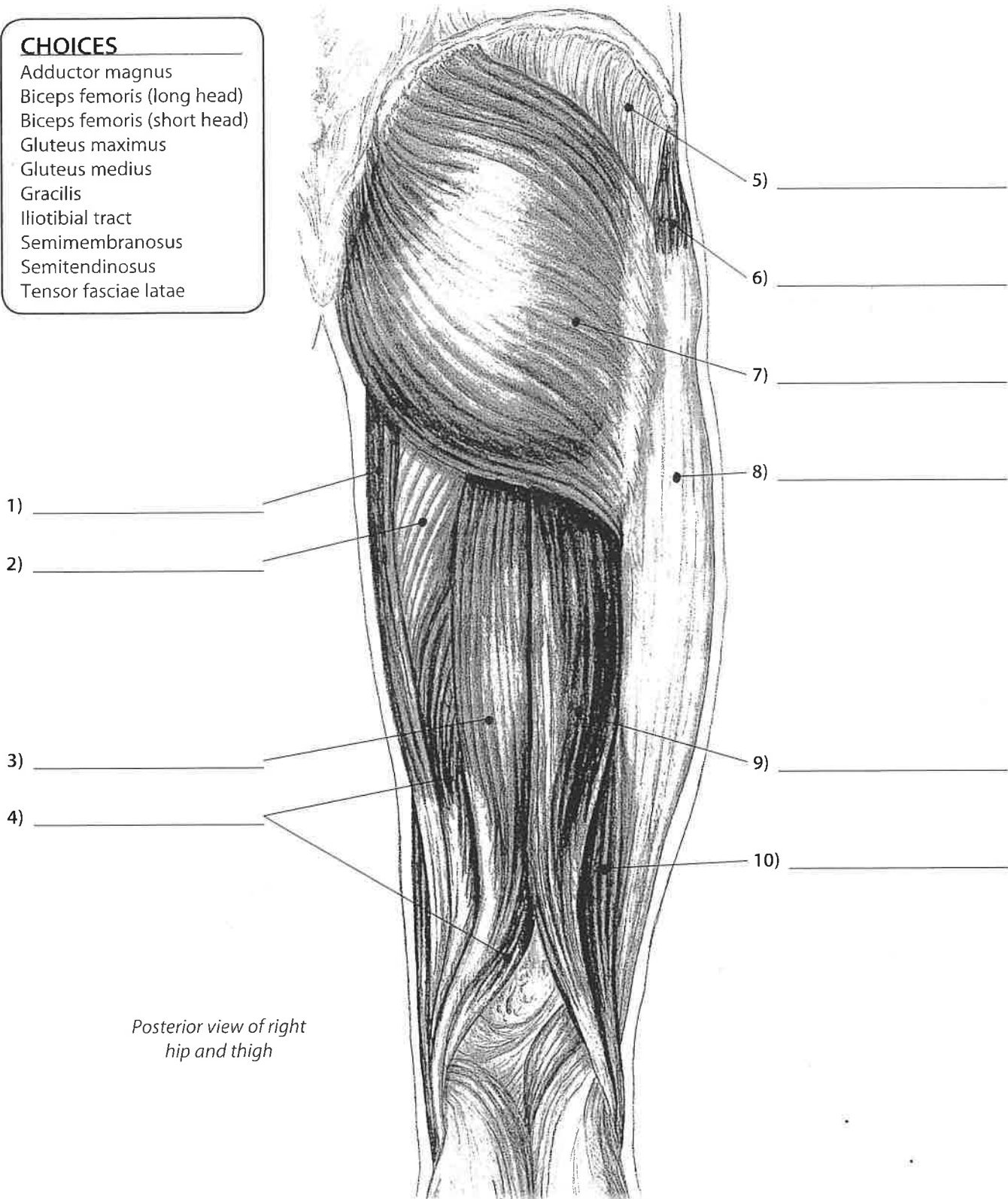
- CHOICES**
- Adductor longus
 - Gracilis
 - Iliacus**
 - Iliotibial tract
 - Iliopsoas**
 - Pectineus
 - Psoas major
 - Psoas minor
 - Rectus femoris
 - Sartorius
 - Tensor fasciae latae
 - Vastus lateralis
 - Vastus medialis



Please identify the following structures.

CHOICES

- Adductor magnus
- Biceps femoris (long head)
- Biceps femoris (short head)
- Gluteus maximus
- Gluteus medius
- Gracilis
- Iliotibial tract
- Semimembranosus
- Semitendinosus
- Tensor fasciae latae



Posterior view of right hip and thigh

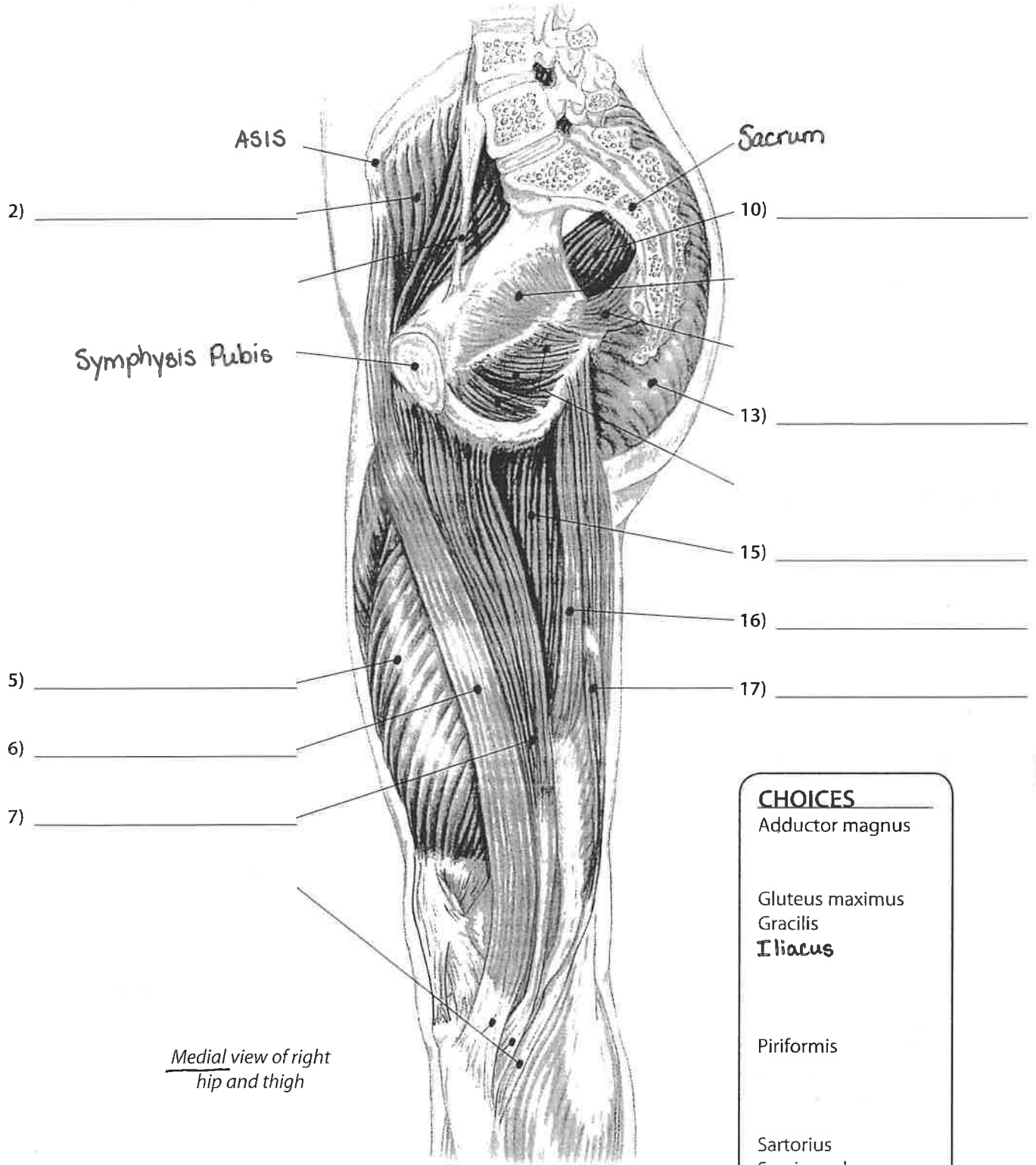
Pelvis & Thigh

Pelvis and Thigh

Muscles of the Pelvis and Thigh #4



Please identify the following structures.



Medial view of right hip and thigh

CHOICES

- Adductor magnus
- Gluteus maximus
- Gracilis
- Iliacus**
- Piriformis
- Sartorius
- Semimembranosus
- Semitendinosus
- Vastus medialis

Pelvis & Thigh



Muscles of the Leg and Foot #2

Please identify the following structures.

CHOICES

- Gastrocnemius (2)
- Peroneus brevis (2)
- Peroneus longus (2)
- Soleus (2)
- Tibialis anterior (2)

